

DARKROOM PROCEDURES : ENLIGHTENED



Introduction

Dark-room procedures (DRP) constitute an essential part of the examination of the eye beside being an important part of the undergraduate professional examinations.

The main DRPs are:

1. Preliminary examination at 1 m (including Retinoscopy).
2. Distant Direct Ophthalmoscopy at 22/25 cm.
3. Indirect Ophthalmoscopy.
4. Direct Ophthalmoscopy.

Other topics covered in this text are:

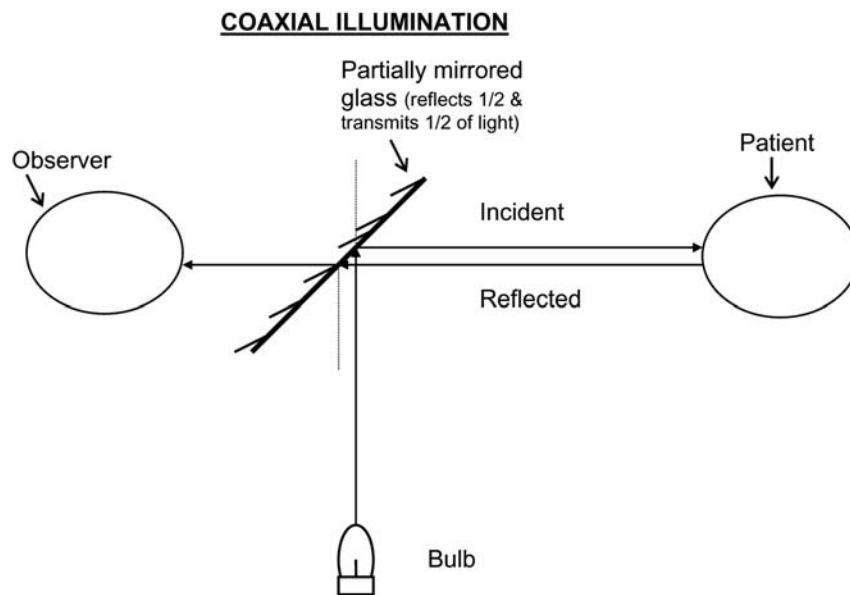
- ▶ Lenses
- ▶ Prisms
- ▶ Appliances (Retinoscope, Pin-hole, etc.)

All DRP are performed in very low ambient illumination (not necessarily pitch dark) and with the examiner preferably dark adapted. Before describing DRP it is important to understand the principle of coaxial illumination which is applicable to all DRP.

Coaxial Illumination

Why does the pupil appear black no matter how bright light we use to examine the eye? And why does it appear red when seen through ophthalmoscope or retinoscope even with very faint light? A very basic principle of optics is that in any ideal optical system the light rays retrace their own path. Therefore the light rays from the torch-light falling into the eye get reflected back in the same direction and since the observer's eye is not a source of light, no light comes in that direction and therefore the pupil appears black (in eyes with high refractive errors the pupil may appear red because the eye is no longer an ideal optical system).

However the ophthalmoscope or retinoscope have an ingenious optical system of coaxial illumination i.e. the axis of illumination and the axis of observation are in same line making the eye of the observer a virtual source of light, as depicted in the diagram below:



The light reflected from the patient's eye gets transmitted through the partially mirrored glass and falls into the observer's eye, therefore the pupil appears red (the fundal glow).

What is the color of the retina? Theoretically purple because of the pigment visual purple (as deciphered from its absorption/emission spectrum) but in practice when any amount of light falls on the retina the pigment gets bleached making it almost transparent. Then why does the fundal glow appear red? Because of the light reflected from the choroidal vasculature.

I. Preliminary Examination at 1m (including Retinoscopy)

Patient is seated in a dimly lit room with light source above and behind patient's left shoulder. Observer sits at 1m and using plane mirror of the Priestley-Smith Retinoscope (described later) light is reflected onto patient's eye while looking through its hole. If the ocular media are clear the pupil appears red due to fundal glow.

Retinoscopy (or Skiascopy) is an objective method of determining the refraction of the eye (not to be confused with ophthalmoscopy which means visualization of the retina).

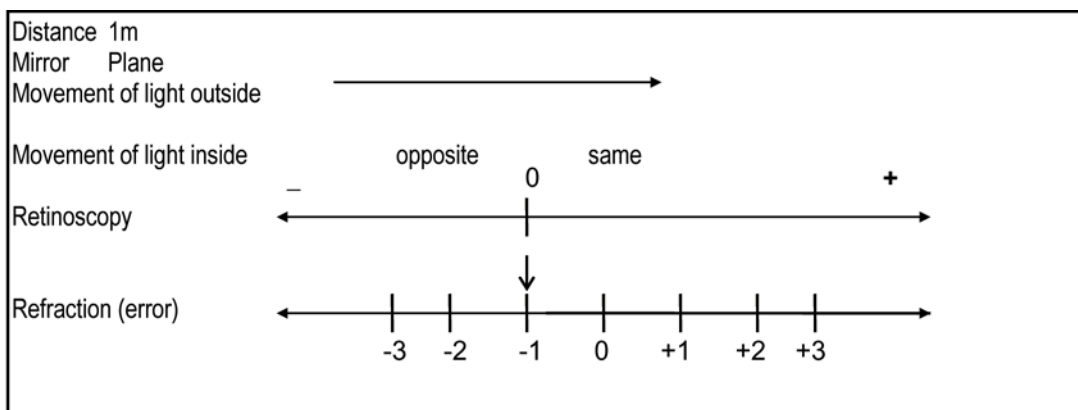
To understand the methodology of retinoscopy we will make following assumptions:

1. Done at 1m.
2. Using plane mirror.
3. We move the light (or the mirror) from our left to our right.

The reflected light from plane mirror is moved across the patient's eye by turning the mirror from left to right while the movement of the glow (light) in the pupil is observed. There are 3 possibilities:

1. Glow in the pupil moves in the same direction as the light outside. This means the patient can be any of the following:
 - ▶ Hypermetropic
 - ▶ Emmetropic
 - ▶ Myopic less than -1.0 D
2. Glow in the pupil moves in the opposite direction. This means patient is myopic by more than -1.0 D.
3. Glow does not move (and the pupil is either uniformly lit or uniformly dark). This means patient has myopia of 1.0D.

Above assertions can be easily remembered by studying the following diagram:



It may be seen from the retinoscopy line that if the glow moves in the + (same) direction patient is anywhere on the + side and if the glow moves in the - (opposite) direction the patient is anywhere in the - side; but in both these situations we do not know where exactly the patient is. However, when the glow in the pupil does not move that we know for certain that the patient has myopia of -1.0 D. So what do we do if the glow moves in the same or the opposite direction? We neutralize the movement i.e. bring the optical system to the point where the glow stops moving, by putting in front of the eye increasing power of + or - lenses depending on + or - direction of movement of glow, respectively. If the glow moves in the + (same) direction we neutralize it by + lenses and if it moves in the - (opposite) direction then by - lenses. When the glow stops moving then the 'optical system' viz. the eye of the patient and the lens in front of it, has come to the point of neutralization and therefore has myopia of -1.0 D. Now if we prescribe -1.0 D lens to this 'optical system' it will become emetropic, which is same as adding -1.0 to the power of lens in front of the eye (the retinoscopic value). Thus, we get the refractive error of the patient.

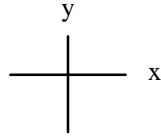
Examples:

- ▶ If the movement in the same direction gets neutralized by +5.0D lens then the refractive error is +4.0D (-1.0 added algebraically to +5.0).
- ▶ If movement in the same direction is neutralized by +1.0D then the error is 0.0 i.e. the patient is emetropic[-1+(+1)].
- ▶ If movement in same direction is neutralized by +0.25D then the error is -0.75D[-1+(+0.25)].
- ▶ If the movement in the opposite direction is neutralized by -1.0D then the error is -2.0D[-1+(-1)].

NB:

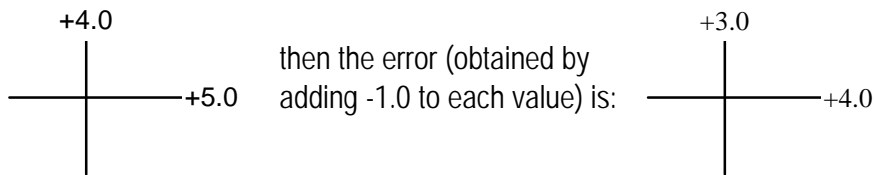
1. The higher the refractive error the fainter the glow in the pupil and slower does it move. But as one approaches the point of neutralization the glow gets brighter and moves faster. And at the point of neutralization the glow is the brightest and completely fills the pupil.
2. In some cases direction of movement of glow is not clearly defined, instead there is scissoring of the glow; here the point of neutralization is reached when two limbs of the scissors start from the center of the pupil and move equally in opposite directions.
3. If two light reflexes are seen, one central and the other peripheral, then one should neutralize the central glow because the central parts of cornea and lens are more important in forming image on the retina.
4. Theoretically the ideal distance for doing retinoscopy is infinity (∞) because the retinoscopy directly gives the refractive error. The neutralization point correspond to myopia of -1, distance in meter which is also the amount to be added to the retinoscopy value.
5. At neutralization point the patient's and the observer's eyes become conjugate foci of the optical system (as the image of the illuminated points on the patient's retina are formed at the observer's pupil).

The method described above gives refractive error only in the horizontal meridian, whereas the error may not be the same in all meridians as is seen in astigmatism. However, as most patients have regular astigmatism in which two principal meridians disposed at right angle to each other can be defined. Also, these meridians are most commonly aligned vertically and horizontally. Therefore, it is customary to do retinoscopy both vertically and horizontally, and note the values separately as follows:



where x denotes retinoscopy value along horizontal meridian and y denotes the value along the vertical meridian (obtained by moving the mirror vertically). If these two values are equal then there is no astigmatism and a spherical lens alone will correct the error. But if these two values are not equal then it denotes presence of astigmatism which needs a cylindrical lens (alone or in combination with a spherical lens) for its correction, as explained next.

A **cylinder** is a lens which has refractive power only in one meridian (i.e. at right angle to its axis) and no power at right angle to it (i.e. along the axis). Now if the retinoscopy values are e.g.:



Now a +3.0 D spherical lens would completely correct the vertical meridian and would partly correct the horizontal meridian leaving a residual error of +1.0 D [$+4.0 - (+3.0) = +1.0$]. This is corrected by +1.0 D cylinder whose axis is placed at 90° (vertically) because the power is required to act at 180° (horizontally).

Thus the prescription would be:

+3.0 D sphere / +1.0 D cylinder at 90°

Study the following examples carefully:

| Retinoscopy | Refractive error | Prescription |
|---|--|--|
| 1. $\begin{array}{c} +1.50 \\ \\ \text{---} +2.75 \\ \end{array}$ | $\begin{array}{c} +0.50 \\ \\ \text{---} +1.75 \\ \end{array}$ | +0.50 D sph/ +1.25 D cyl at 90° |
| 2. $\begin{array}{c} +1.75 \\ \\ \text{---} +1.0 \\ \end{array}$ | $\begin{array}{c} +0.75 \\ \\ \text{---} +0.0 \\ \end{array}$ | +0.75 D cyl at 180° |
| 3. $\begin{array}{c} -2.25 \\ \\ \text{---} -0.25 \\ \end{array}$ | $\begin{array}{c} -3.25 \\ \\ \text{---} -1.25 \\ \end{array}$ | -1.25 D sph / -2.0 D cyl at 180° |
| 4. $\begin{array}{c} +0.5 \\ \\ \text{---} +1.50 \\ \end{array}$ | $\begin{array}{c} -0.50 \\ \\ \text{---} +0.50 \\ \end{array}$ | -0.5 D sph / +1.0 D cyl at 90° OR +0.5 D sph / -1.0 D cyl at 180° |

In the last example both the prescriptions are correct and one is the transposition of the other.

Transposition means an equivalent prescription with the cylinder of opposite sign. While transposing a prescription the spherical-equivalent (and not the sphere) of the lens is kept constant. Following are the steps to transpose a prescription:

- ▶ Algebraic sum of the sphere and the cylinder gives the new sphere.
- ▶ Same cylinder with opposite sign.
- ▶ Axis is placed at right angle to the previous axis.

Spherical Equivalent of a spherocylindrical lens (combination of a sphere and cylinder) is a spherical lens with same average refractive power obtained by algebraically adding half the value of the cylinder to the sphere. Note the focal point of the spherical equivalent coincides with the circle of minimal blur of the spherocylindrical lens.

The use of Cycloplegia in retinoscopy

In retinoscopy a common source of error is accommodation which is most active in young patients. When patient accommodates the refractive power of the eye increases resulting in a variable shift towards myopia. A simple solution would be to relax the accommodation by the use of a cycloplegic but cycloplegia leads to abolition of basal tone of the ciliary body muscles resulting in manifestation of latent hypermetropia. So if the patient accommodates there is a shift towards myopia, and if we use cycloplegia there is a shift towards hypermetropia; however, the latter situation is preferable as the amount of shift towards hypermetropia caused by a given cycloplegic is known and the same amount can be reduced from the retinoscopy value to get the refractive error.

Cycloplegic-Mydriatic Agents

| Preparation | Dosage | Age Group of patient | Amount to be reduced | Duration of action | Complication |
|---------------------------------------|------------------------------|----------------------------------|------------------------------------|--------------------|--|
| 1. Atropine sulfate 1 % oint. | TDS 3 days | 0 to 5 years | 1.0 to 1.5 D | 2 to 3 weeks | Allergy, Fever, Flushing of face, etc. |
| 2. Homatropine hydrobromide 2 % drops | every 15 min. 4 applications | 5 to 7 years | 0.5 to 1.0 D | 24 to 48 hr. | Dry mouth, Urine retention in old |
| 3. Cyclopentolate HCl 1% drops | every 15 min. 4 applications | 7 to 20 years | 0.5 to 1.0 D | 12 to 24 hr. | Transient psychotic reaction |
| 4. Tropicamide 0.5-1 % drops | every 15 min. 4 applications | not specified | 0.25 to 0.5 D | 2 to 4 hr. | Dry mouth |
| 5. Phenylephrine HCl 5-10 % drops | every 15 min. 4 applications | where only mydriasis is required | Nil (it has no cycloplegic action) | 6 to 8 hr. | Increase in BP in hypertensives |

NB- For patients of 20 to 30 years of age cycloplegia is used if needed in a particular case, and after the age of 30 years cycloplegia is not required.

When retinoscopy is done under cycloplegia, patient is not prescribed glasses at the same time but patient is examined again after the effect of the cycloplegic has worn off i.e. usually after 1 week, for subjective verification (post cycloplegic test). However, patient's acceptance of the refractive correction is determined the same day. Therefore, the sequence of steps of refraction are:

1. Retinoscopy under cycloplegia.
2. Get the acceptance by adding -1_{m} distance (m). If the distance is 1 m then add -1_{m} i.e. -1.0
3. Prescribe after cycloplegia is worn off by reducing from above value the amount for given cycloplegic used.

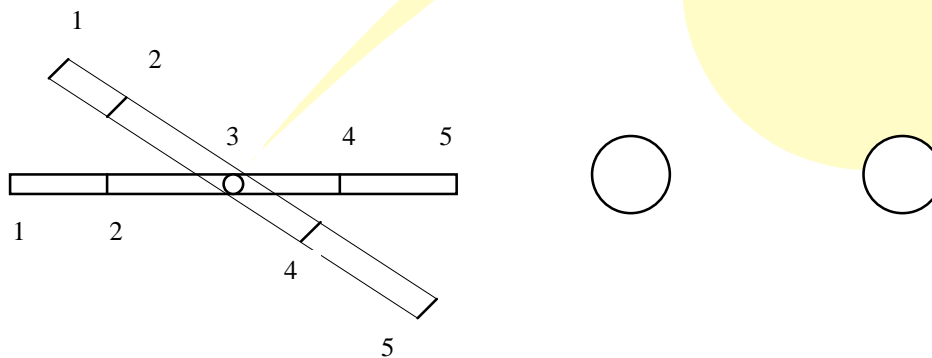
Note that the amount for cycloplegia is reduced only from the spherical component of the refractive correction.

II. Distant Direct Ophthalmoscopy (DDO) at 22 cm using plane mirror

After preliminary examination at 1 m examiner moves closer to the patient to a comfortable near vision distance of 22 cm (or 25 cm and concave mirror

according to some authors). In a normal eye with clear media one can see red fundal glow in the pupil. The abnormalities that can be observed by this method are as follows:

1. Opacity in the media (cornea, aqueous, lens and vitreous) will appear black against the background of red fundal glow. The opacity appears black because no light goes in the eye or comes out of it from the area of opacity.



2. Depth of opacity (Parallaxial Displacement) can be estimated qualitatively by the method of parallaxial displacement. While observing the pupil patient is asked to move the eye up, down, right and left. An opacity located in the pupillary plane does not seem to move relative to the pupil whereas any opacity anterior to the pupil seems to move in the same direction and an opacity posterior to the pupil seems to move in opposite direction. The further away an opacity is from the pupillary plane the more does it move in relation to the pupil. This can be easily understood by studying the diagram above. If we take a rod which is hinged at point 3, and turn it up. The points 1 and 2 which are in front of the hinge move in the same direction and points 4 and 5 behind the hinge move in the opposite direction, whereas the point 3 which is in the plane of the hinge does not seem to move. When looked at end-on it appears like the figures on the right with the circles representing the pupil. The pupil acts a frame to which all the movements are referred. Contrary to expectation the reference plane in the eye is not the center of rotation because the movement of any opacity can be appreciated only in relation to the pupil.
3. Opacity in fluid or solid part of the media can be differentiated by observing the after-movement of the opacity i.e. movement of the opacity after the eye has halted. Presence of after-movement denotes opacity in the fluid part of the media (aqueous or vitreous).
4. Keratoconus gives rise to a ring-shadow corresponding to the base of the cone of the keratoconus. It occurs despite the fact that the cornea is transparent, because of total internal reflection of light occurring at the base of the cone. This reflects the light back into the eye and, thus, the base of the cone appears as a dark ring. Similar ring shadow may also be seen in lenticonus and the two can be differentiated by parallaxial

displacement.

5. Iris nevus and coloboma, both of which appear as black patch on the iris, can be differentiated by DDO. Coloboma being a defect in the iris permits light to pass through it making fundal glow visible. However, glow cannot be seen across the nevus.
6. Cataract can be easily differentiated from nuclear sclerosis which also appears gray with torch light examination. Cataract appears as dark opacity against fundal glow but in nuclear sclerosis the media are clear. Moreover, as long as some clear cortex is present in cataract some fundal glow is visible, thus differentiating immature from mature cataract. In mature cataract no glow is seen, rather pupil appears gray even with DDO due to light reflected from the cataract.
7. Subluxation of clear lens is not obvious on examination with torch light as the pupil appears dark. With the DDO the edge of the lens crossing the pupil stand out as a dark crescent against fundal glow. Though the lens is clear yet the edge appears dark because of total internal reflection of light at lens edge.
8. Lens Coloboma, a notch like defect in lens edge can be readily seen with DDO.
9. Vitreous hemorrhage in its milder form gives rise to darkening of the red fundal glow which then appears deep red or maroon. In severe vitreous hemorrhage no glow can be seen and pupil appears dark as whatever light gets reflected from fundus is absorbed by the blood pigments.
10. Retinal Detachment (RD) is separation of the neural layer of retina from the retinal pigment layer leading to loss of nutrition of the former from the choroidal vasculature. As a result of this the retina becomes grayish opaque and lies much anteriorly (closer to the lens). This gives rise to grayish glow in the area of RD and makes that part of the retina visible by DDO (detached retina becomes highly hypermetropic). Retinal folds may be seen moving with the movement of the eye and retinal vessels running over the folds as dark bands.
11. Retinal Tumors are also visible on DDO as gray glow and sometimes the mass itself can be seen with a bunch of abnormal vessels on it. Unlike RD no folds are seen and there is no after-movement in retinal tumor.
12. Gray glow on DDO; other causes are:
 - ▶ Fundus coloboma
 - ▶ Posterior staphyloma
 - ▶ Medullated nerve fibers in the retina (around the optic disc)

III. Indirect Ophthalmoscopy

Ophthalmoscopy means visualization of the fundus oculi. In principle, indirect ophthalmoscopy involves making the eye highly myopic by placing a high power convex lens (+13, +20 or +28 D) in front of the eye so that a **real inverted** image is formed in front of the lens.

Classically indirect ophthalmoscopy was done using concave mirror of the Priestly-Smith retinoscope but now it is done using a head mounted binocular indirect ophthalmoscope. Patient lies on a couch with the pupils fully dilated. The examiner stands at the head end of the bed and directs the light of the ophthalmoscope onto the patient's eye and while looking at the pupil interposes the convex lens in front of the eye, then moving the lens away from the eye till the retina is seen clearly. A real inverted image which is 3 to 5 times magnified is formed in between the lens and the observer. The magnification depends on the power of the lens used and the refraction of the eye and is given by the refraction of the eye divided by the power of the lens used e.g. $60 \text{ D} \div 13 \text{ D} = 5$ approx.

| Advantages | Disadvantages |
|--|--|
| <ol style="list-style-type: none"> 1. Stereopsis: the greatest advantage is the 3 dimensional view possible with this method which lets the depth or the solid nature of a lesion to be appreciated. 2. Large field of view enables a wide area of the retina to be seen at a given time (about 30°). Thus a large lesion e.g. retinal-detachment, tumors, etc. can be observed in its entirety. 3. Periphery of the retina can be seen, even up to ora serrata (combined with indentation of the sclera) by this method. So the peripheral retinal lesions e.g. retinal degenerations, breaks or holes etc. may be visualized. 4. Vitreous can be easily examined and various vitreous abnormalities diagnosed. 5. In hazy media this method is useful because the illumination is very bright and the method does not make use of the refractive system of the eye, thus being of immense benefit in corneal haze, cataract, vitreous hemorrhage, etc. 6. This can be used intra-operatively as there is reasonable distance between the patient and the examiner so various maneuvers can be done on the eye, and also the lens used for the purpose can be sterilized. | <ol style="list-style-type: none"> 1. The technique is difficult to learn as the image is inverted; the orientation being achieved with lot of practice. Although by examining the patient from the head end of the bed the retina is inverted thus resulting in an 'erect' image yet coordinating the indentation of the sclera with the observed image requires learning. 2. It is very difficult to use this method in an upright patient. 3. The instrument is bulky and therefore not easily portable. 4. Magnification is less, therefore the small lesions e.g. macular pathology, cannot be examined in all their details. |

IV. Direct Ophthalmoscopy

First given by Herman von Helmholtz, ophthalmoscopy is classically done by just a plane mirror making use of the optical system of the patient's eye. The light of the hand held self illuminated ophthalmoscope is directed to patient's pupil while observing it through the fenestration in the ophthalmoscope. The examiner approaches the patient's eye to a distance within anterior principal focus i.e. about 15 mm, where a virtual erect image of the fundus is seen formed behind patient's eye. The optical system of the eye acts as a simple microscope which magnifies the image about 15 times. The magnification can be derived by dividing the dioptric power of the eye by 4, thus $60 \div 4 = 15$. The magnification is more in myopia and less in hypermetropia.

| Advantages | Disadvantages |
|--|---|
| <ol style="list-style-type: none"> 1. Easy to use and portable. 2. Greater magnification enables fine details to be examined. 3. Patient can be examined in any position. 4. Erect image does not cause any difficulty in orientation. | <ol style="list-style-type: none"> 1. No stereopsis. 2. The illumination is low therefore if media are hazy the visibility is poor. 3. Cannot be used for operative procedures because of close proximity with the patient and inability to sterilize the ophthalmoscope. 4. Field of view is small and the retinal periphery cannot be seen. |

APPLIANCES

I. PIN-HOLE

A black disc with a 0.5 to 1.5 mm diameter fenestration in the center.

Uses:

1. Diagnosis of refractive error - to differentiate the diminution of vision caused by refractive errors from any other cause. Pin-hole is placed in front of the patient's eye if the vision improves to (nearly) normal then it denotes that the diminution is caused by refractive error otherwise an organic cause may be present. The pin-hole allows only a very narrow pencil beam of parallel rays to pass through the optical center of the eye, which does not need any refraction to form a sharp image on the retina. In cases with central media opacity and macular pathology the vision may deteriorate with the pin-hole because pin-hole cuts out light from the peripheral media and forms clear image on the macula.
2. Confirmation of the refractive correction is done by placing a pin-hole in front of the corrective lenses, if the vision improves further it means the correction applied is imperfect and needs improvement.
3. Unilateral diplopia or polyopia is differentiated from binocular diplopia by placing the pin-hole in front of the eye with diplopia. Elimination of diplopia denotes that the diplopia is unilateral.
4. Two point discrimination test is done using a disc with 2 pin-holes 2mm apart placed close to the eye and a point source positioned 2 feet behind the disc. If the patient sees 2 images of the point source of light then the macular function is inferred to be normal.
5. As a low vision aid - patients with irregular cornea whose refractive error cannot be corrected by glasses, can be benefited by using opaque discs with multiple pin-holes which provide refractive correction whichever direction the patient gazes.
6. As an aperture pin-hole is used in various optical instruments to control the amount of light passing, increase the depth of focus and cut off the internal glare generating within the tubes of the instrument.
7. Rest to the eye can be ensured by making the patient wear opaque glasses with only one pin-hole in front of each eye. This forces the patient to move his head to view his surroundings rather than moving his eyes. This method was used in past in patients with traumatic hyphema and fresh retinal detachment.

II. STAENOPIC SLIT

This is an opaque black disc with a 1 mm thick slit running across the center.

Uses:

1. Astigmatism can be diagnosed with a staenopic slit. It is placed in front of the patient's eye and slowly rotated by 180°. If the vision of the patient is significantly better in a particular position than others then astigmatism is present. The axis of the slit represents the axis of one of the two principal meridians. The staenopic slit has the same effect as the pin-hole but only in one meridian which is at right angle to the slit itself.
2. Confirmation of the power and axis of the cylinder can be made by placing the staenopic slit in front of the cylinder along its axis. If the vision of the patient improves further then the power of the cylinder is imperfect. Then the axis of the slit is varied about the axis of the cylinder and if the vision improves then the axis of the cylinder is required to be changed accordingly.
3. Fincham's test is done using the staenopic slit to differentiate the colored haloes caused by cataract (lenticular) from that caused by glaucoma (corneal). Staenopic slit is moved across patient's eye while the patient looks at a bright point source of light which gives rise to halo. The halo caused by cataract breaks into a fan the blades of which seem to move whereas the halo caused by glaucoma remains unchanged or just becomes a little faint. This is caused by peculiar disposition of the lens fibers which cause diffraction of light parallel to them.
4. Determination of meridian of optical iridectomy is done with the help of staenopic slit. A patient who has a small central corneal or lens opacity may benefit from optical iridectomy. Vision is first recorded with the normal pupil then the pupil is dilated and staenopic slit is placed in front of the eye and rotated: the axis where vision improves markedly, is chosen for optical iridectomy. Although empirically the optical iridectomy is done inferonasally in patients whose occupation involves near work, and temporally for out-door workers.

III. MADDOX ROD

Maddox rod or groove is a set of high power micro cylinders placed close and parallel to each other. It converts a point source of light in to a line image at right angle to its axis. Therefore, a point source of light seen through Maddox rod with the axis placed horizontally, appears to be a vertical line.

Uses:

1. Latent squint can be diagnosed by placing Maddox rod in front of one eye and asking the patient to look at a bulb in the center of Maddox cross mounted on a wall. Patient sees bulb with the bare eye and a vertical line with the other eye. If the eyes are aligned the bulb is seen in the center of the line. Whereas if there is a latent squint the bulb is seen away from the line or eccentric on the line. In esophoria the line is seen on the same side as the eye with Maddox rod (uncrossed diplopia) and in exophoria on the opposite (crossed diplopia). The amount of deviation can be measured by neutralizing the misalignment by putting prism in front of the Maddox rod or by reading the scale mark corresponding to the line as seen on the Maddox cross.

2. Macular function test is performed by placing Maddox rod in front of the eye with opaque media and shining a bright torch on it. With normal macula the patient sees a smooth, continuous and unbroken straight line. If the macular function is deranged patient sees an irregular or broken line.
3. Double Maddox rod test is done for the diagnosis of cyclotropia or torsional squint. Two Maddox rods, one red and the other white, are placed in front of the two eyes with the axes vertically. A 4^D base-down prism is placed in front of one of the rods to displace one of the lines upwards. A patient without any cyclotropia will see two parallel lines one above the other. Patient with cyclotropia will see one horizontal line and one tilted line. He is then instructed to rotate the Maddox rod corresponding to the tilted line such that the two lines become parallel to each-other. The axis of this rod gives the degree of cyclo-deviation.

IV. CONVEX LENS

Convex or plus lens is the one that converges the rays of light (or decreases divergence).

Identification is done by holding the lens close to eye and moving it side ways while looking at a distant target. The target seems to move in the opposite direction. Then the lens is rotated while still viewing a distant target, there is no distortion of the image in a spherical lens (as opposed to a cylindrical lens).

Uses:

The convex lenses are used for following:

1. Hypermetropia
2. Presbyopia
3. Aphakia
4. Accommodative esotropia
5. Indirect ophthalmoscopy
6. Corneal loupe
7. As part of (almost all) optical instruments

V. CONCAVE LENS

Concave or minus lens diverges the rays of light (or decreases convergence).

Identification is done by the method described above for convex lens, however, the target seems to move in the same direction and there is no distortion on rotating the lens.

Uses:

The concave lenses are used for following:

1. Myopia
2. Hruby lens (-57.8 D), which is a high power concave lens, is used for visualizing the fundus on the slit-lamp examination.
3. As part of various optical equipment.

VI. CYLINDER

A cylinder is a lens which has refractive power only in one meridian but not at right angle to it. It should be noted that the power of cylinder acts at right

angle to it. So if power is required vertically the cylinder axis is placed horizontally and vice versa.

Identification is made by placing the lens close to eye and looking at a distant target. On moving it horizontally or vertically target will move only with one movement, and on rotation the image shows distortion. In convex cylinder the image seems to move in opposite direction and in concave cylinder it moves in the same direction.

Use:

Cylinders are used to correct astigmatism.

VII. TORIC LENS

A toric or spherocylindrical lens is a combination of a sphere and a cylinder.

Identification: On moving the lens the image seems to move in one or the other direction (depending on convex or concave), regardless of which direction the lens is moved. And on rotation there is distortion of the image.

Uses:

Toric lenses are used to correct the following:

1. Compound astigmatism
2. Mixed astigmatism

VIII. PRIESTLEY-SMITH RETINOSCOPE

It is a device which has a plane and a concave mirror with following properties:

1. Plane mirror

- ▶ it is actually a very slightly concave mirror with a focal length of 1.5 m.
- ▶ a fenestration (hole) in the center.
- ▶ central hole is 2.5 mm on the mirrored side and tapers out to 4 mm on the polished side.
- ▶ the wall of the hole is painted dull black

Uses:

- ▶ Preliminary examination at a distance of 1 m
- ▶ Retinoscopy
- ▶ DDO

2. Concave mirror

- ▶ Focal length 25 cm.
- ▶ Central hole with same features as above.
- ▶ In past the central hole used to contain a +2 D convex lens to relax the accommodation of the observer. Although the convex lens is no longer placed in the hole yet the manufacturers continue to print +2 at the back of concave mirror.
- ▶ Looking into it the viewer's own eye appears magnified (method of identification).

Uses:

- ▶ Retinoscopy in patients with hazy media, high refractive error where the glow is faint and for confirmation of the point of neutralization.
- ▶ Indirect ophthalmoscopy (as described classically).
- ▶ Although not described conventionally yet DDO may be done by the mirror.

IX. PRISM

A prism is an optical device which deviates the path of light without converging or diverging the rays light. The light rays deviate towards the base whereas the image is shifted towards the apex. The angle of deviation is half the angle of the prism (α) i.e. $\alpha/2$. The power of the prism is measured in prism diopters (D); one prism diopter denotes displacement by 1 cm of the image of an object placed at 1 m from the prism. The power of the prism can be measured by any of the following methods:

- ▶ Neutralization by prisms of known power.
 - ▶ Projection vertexometer
 - ▶ Focimeter or lensometer
 - ▶ Viewing the Maddox cross or tangent scale through the prism and noting the reading corresponding to the displaced image of the bulb.
- Identification is made using the same method described for lenses. On moving the prism sideways there is no movement of the image. On rotating the prism there is no distortion of the image, however, the image seems to swirl around the base of prism. The base is marked + on the rim and the apex is marked -.

Uses:

1. Diagnostic
 - ▶ Objective measurement of the angle of squint.
 - ▶ Subjective measurement of the angle of squint.
 - ▶ Measurement of fusion range.
 - ▶ Preoperative assessment of possibility of postoperative diplopia.
 - ▶ 4^D base-out prism test for microtropia.
 - ▶ Test for malingering
2. As part of (following) instruments
 - ▶ Indirect ophthalmoscope
 - ▶ Slit-lamp biomicroscope
 - ▶ Operating microscope
 - ▶ Gonioscope
 - ▶ Applanation tonometer
3. Therapeutic
 - ▶ To relieve diplopia in cases of paralytic squint while they are waiting for surgery.
 - ▶ Severe convergence insufficiency which does not respond to conservative treatment.